


Case Report

A rare case of recurrent biballism

Ankur Banik¹ , Moukoli Pal¹, Sandip Pal¹, Indranil Dutta¹, Amrit Chattopadhyay¹

¹Department of Neurology, Medical College and Hospital, Kolkata, West Bengal, India.



***Corresponding author:**

Ankur Banik,
Department of Neurology,
Medical College and Hospital,
Kolkata, West Bengal, India.

banik.ankur@gmail.com

Received: 21 October 2023
Accepted: 03 March 2024
Epub Ahead of Print: 30 April 2024
Published: 21 September 2024

DOI
10.25259/MEDINDIA_28_2023

Quick Response Code:



ABSTRACT

Diabetic striatopathy (DS) is a relatively new entity with growing literature expanding our knowledge of the same. It is commonly seen in elderly Asian females with long-term uncontrolled type 2 diabetes mellitus presenting with hemichorea or hemiballism with characteristic reversible imaging findings involving various basal ganglia structures. While various different types of presentations with variable responses to therapy in terms of treatment modality and recovery time have been reported, there is very little data on the recurrence of this entity. We, hereby, present an interesting case of DS, which had a rare presentation in the form of biballism. Our patient had an initial swift recovery with glycemic control alone and thereafter a ropinirole-induced recurrence in spite of good glycemic control, which was rather difficult to control. This case emphasizes the need for clinicians to be aware of the various presentations of DS and to be cautious in the use of drugs with the potential to cause movement disorders in such a patient.

Keywords: Biballism, Recurrent movement disorder, Acute movement disorder, Diabetic striatopathy, Recurrent ballism

INTRODUCTION

Ballism, or ballismus, from the Greek word for “to throw,” refers to flinging or flailing movements that are non-patterned, usually involving proximal muscles of the limbs. Ballism is usually confined to one side of the body, called hemiballism; rarely, both sides are affected, called biballism. Diabetic striatopathy (DS) is a relatively new entity, and most cases present with hemichorea or hemiballism. Bilateral presentation is rather uncommon, and, biballism even more so. Nevertheless, we describe here an unusual case of biballism as a manifestation of DS, which initially completely disappeared swiftly after correction of hyperglycemia alone, but was followed by a probable drug-induced recurrence, which was far more difficult to control.

CASE REPORT

A 50-year-old male patient with long-term, poorly controlled type 2 diabetes presented with acute onset Biballism without any other neurological or systemic symptoms or signs. At that time, his initial blood glucose and hemoglobin A1c (HbA1c) were 300 mg/dL and 10.4, respectively, and his movements were promptly controlled with glycemic control alone with insulin in 3-4 days. He was discharged in stable condition with advice to continue insulin, and he was doing perfectly well. Two months later, he again developed biballistic movements of similar phenomenology and got readmitted. Seven days before the current admission, he consulted a local doctor, where

This is an open-access article distributed under the terms of the Creative Commons Attribution-Non Commercial-Share Alike 4.0 License, which allows others to remix, transform, and build upon the work non-commercially, as long as the author is credited and the new creations are licensed under the identical terms.

©2024 Published by Scientific Scholar on behalf of Medicine India

he was prescribed ropinirole for suspected restless legs syndrome, and he had developed these movements 4-5 days after starting the new medication. Clinical examination was noncontributory except the biballism. Interestingly, blood glucose on admission this time around was 86 mg/dL, and regular blood glucose charting also showed normal readings throughout.

Investigations were as follows:

Complete blood count: All within normal limits (WNL)

HbA1c: 10.1

Liver, kidney, and thyroid function tests: All WNL

Serum sodium 134 mEq/L, potassium 4.2 mEq/L, and calcium 9.2 mEq/L

Viral serology (hepatitis B, C and human immunodeficiency virus HIV): All negative

Anti-nuclear antibody and autoantibody panel: Negative

Urine ketones: Negative

Serum and urine osmolality: WNL.

Imaging done during the initial and subsequent presentations is shown in the figures below. During the first presentation, the computed tomography (CT) brain revealed hyperdensities in the bilateral caudate and putamen which had almost disappeared during the subsequent event [Figures 1 and 2].

This time around, although the blood glucose was well controlled throughout, and also, there was a resolution of imaging findings on CT brain; yet, his movement disorder was rather difficult to control. The newly added drugs were withheld immediately without improvement. Sequential addition of tetrabenazine, clonazepam, and risperidone was required, with which his movements gradually improved finally over a total duration of 6 weeks.

DISCUSSION

The prevalence of DS has been reported to be 1 in 100,000,^[1] which is believed to be underestimated because most primary care physicians initially attending the patient might not be familiar with the condition, especially in developing countries, where it is probably more common.^[2]

Bedwell, in 1960,^[3] first reported a case of hemiballism in a patient with severe hyperglycemia who was treated with blood glucose-correcting drugs. Initially, hyperglycemia, as a cause of hemiballism, was reported sporadically, but now, it is considered the second most commonly reported cause after several recent reports from East Asia have provided a much more complete description of this disorder in more than 60 reported cases.^[4-6] The disorder has been

documented to occur predominantly in elderly females with poorly controlled type 2 diabetes mellitus. Regarding clinical presentations, the large majority of patients presented with chorea or hemichorea. Bilateral involvement was noted in only 9.7% of patients.^[7] Boughammoura-Bouatay *et al.* have previously reported a case of biballism due to non-ketotic hyperglycemia.^[8]

In patients with DS, the average levels of blood glucose and glycated hemoglobin were 414 mg/dL and 13.1%, respectively, in one study,^[7] while another study mentioned an even higher HbA1c average at 14.4%.^[4] In our case, the initial blood glucose was 300 mg/dL and HbA1c was 10.1, suggesting DS can occur in the background of relatively lesser grades of hyperglycemia as well than commonly reported in the literature. Of the patients undergoing an analysis of ketone bodies, the majority (81.7%) were negative for ketone bodies in their blood or urine specimens, as was the case in our patient, and various pathophysiologic mechanisms have been proposed for the same. Although traditionally subthalamic nucleus (STN) has been implicated as the site of lesions for ballism, a review of the more recent literature suggests that lesions outside of the STN accounted for as high as more than half of the reported cases.^[9] The striatum is reported to be the most common non-STN site.

Although initial sporadic case studies proposed that correction of hyperglycemia usually resulted in complete or partial resolution of chorea as well as striatal abnormalities on neuroimaging studies, further subsequent studies have clearly documented that additional anti-chorea drugs might be needed in patients unresponsive to strict glucose control.^[10]

In one study, 26.7% of patients received only glucose control and 73.3% received glucose control with the addition of anti-chorea medications.^[7] Of the patients with documented successful treatment, the median recovery time was significantly shorter in patients undergoing glucose-control-only treatment (2 days) than in those receiving additional anti-chorea medications (14 days).^[7] This was reflected in our case as well.

Since DS is itself rather new, there is very little data regarding the recurrence of the same. The recurrence rate has been postulated to be 18.2% and 13.2% in studies, and hyperglycemia has been implicated as the major cause in the few literature that is available.^[7,4] In our case, since stringent blood glucose monitoring during the second episode showed persistent normal readings, hyperglycemia was unlikely to be the cause of recurrence. Ropinirole, being a dopamine agonist and being definitely temporarily related to the onset, was probably the most likely cause of the recurrence. Even then, the episode did not subside on stopping the probable offending drug and

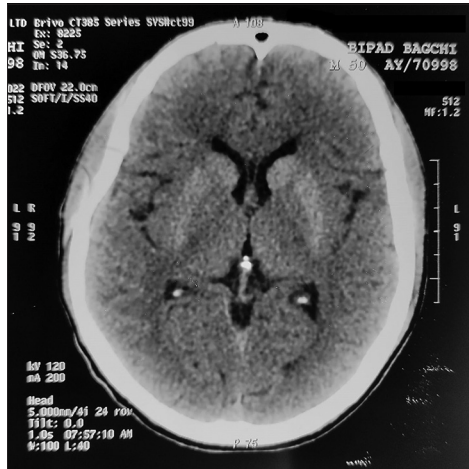


Figure 1: Computed tomography brain during the initial event showing bilateral caudate and putamen hyperdensities.

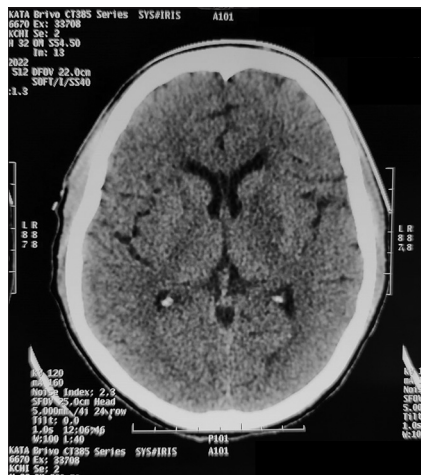

Figure 2: Computed tomography brain during the recurrence showing near-complete resolution of the previous findings.

required multiple anti-dopaminergic drugs, suggesting that probably drug-induced recurrent movement disorder in the background of DS is comparatively more difficult to control.

CONCLUSION

DS can present with multiple different forms of movement disorders, including biballism, as in our case. It is far more common in non-ketotic hyperglycemia than in ketotic hyperglycemia and can manifest in a wide range of initial blood glucose and HbA1c values. Therapeutic response varies greatly, and it can even recur in about 13%-18% of cases. Although hyperglycemia is probably

the most common cause for recurrence, additional probable causes for recurrence should always be sought, especially if the blood glucose levels are found to be normal. Drug-induced recurrence of movement disorder in the background of DS is probably more difficult to treat even with good glycemic control, and hence, in such a clinical scenario, drugs should be used judiciously and with utmost caution.

Ethical approval

The Institutional Review Board approval is not required.

Declaration of patient consent

The authors certify that they have obtained all appropriate patient consent.

Financial support and sponsorship

Nil.

Conflicts of interest

There are no conflicts of interest.

Use of artificial intelligence (AI)-assisted technology for manuscript preparation

The authors confirm that there was no use of artificial intelligence (AI)-assisted technology for assisting in the writing or editing of the manuscript and no images were manipulated using AI.

REFERENCES

- Ondo WG. Hyperglycemic nonketotic states and other metabolic imbalances. *Handb Clin Neurol* 2011;100:287-91.
- Ryan C, Ahlskog JE, Savica R. Hyperglycemic chorea/ballism ascertained over 15 years at a referral medical center. *Parkinsonism Relat Disord* 2018;48:97-100.
- Bedwell SF. Some observations on hemiballismus. *Neurology* 1960;10:619-22.
- Oh SH, Lee KY, Im JH, Lee MS. Chorea associated with non-ketotic hyperglycemia and hyperintensity basal ganglia lesion on T1-weighted brain MRI study: A meta-analysis of 53 cases including four present cases. *J Neurol Sci* 2002;200:57-62.
- Nath J, Jambhekar K, Rao C, Armitano E. Radiological and pathological changes in hemiballism-hemichorea with striatal hyperintensity. *J Magn Reson Imaging* 2006;23:564-8.
- Cosentino C, Torres L, Nuñez Y, Suarez R, Velez M, Flores M. Hemichorea/Hemiballism associated with hyperglycemia: Report of 20 cases. *Tremor Other Hyperkinet Mov (N Y)* 2016;6:402.
- Chua CB, Sun CK, Hsu CW, Tai YC, Liang CY, Tsai IT. "Diabetic striatopathy": Clinical presentations, controversy,

- pathogenesis, treatments, and outcomes. *Sci Rep* 2020;10:1594.
8. Boughammoura-Bouatay A, Chebel S, Younes-Mhenni S, Frih-Ayed M. Biballism due to non-ketotic hyperglycaemia. *Diabetes Metab* 2008;34:617-9.
 9. Postuma RB, Lang AE. Hemiballism: Revisiting a classic disorder. *Lancet Neurol* 2003;2:661-8.
 10. Das L, Pal R, Dutta P, Bhansali A. “Diabetic striatopathy” and ketoacidosis: Report of two cases and review of literature. *Diabetes Res Clin Pract* 2017;128:1-5.

How to cite this article: Banik A, Pal M, Pal S, Dutta I, Chattopadhyay A. A rare case of recurrent biballism. *Med India*. 2024;3:37-40. doi: 10.25259/MEDINDIA_28_2023