

Case Report

Intriguing presentation of congenital diaphragmatic hernia

Vijay Ganesh¹

¹Department of Pediatrics, Base Hospital Delhi Cantt, New Delhi, India.



***Corresponding author:**

Vijay Ganesh,
Department of Pediatrics,
Base Hospital Delhi Cantt,
New Delhi, India.

vijay.bg.ganesh@gmail.com

Received: 20 August 2024
Accepted: 30 September 2024
Epub Ahead of Print: 18 November 2024
Published: 31 December 2024

DOI
10.25259/MEDINDIA_17_2024

Quick Response Code:



ABSTRACT

This case report describes an unusual presentation of congenital diaphragmatic hernia (CDH) in a 3-month-old infant. Typically diagnosed prenatally or at birth due to immediate breathing problems, this infant presented with sudden respiratory distress at 3 months old despite an uneventful medical history. The case highlights the rarity of delayed CDH presentation and emphasizes the need for vigilance even beyond the newborn period. Early diagnosis and surgical intervention are crucial for a favorable outcome. The report also calls for further research to understand delayed CDH presentations and improve diagnostic strategies.

Keywords: Diaphragmatic hernia, Respiratory distress, Pediatric surgery, Surgical emergency

INTRODUCTION

Congenital diaphragmatic hernia (CDH) is a birth defect characterized by a malformation in the diaphragm, the muscular sheet separating the chest cavity (thorax) from the abdomen.^[1] This opening allows abdominal organs, most commonly the stomach and intestines, to protrude into the chest, impeding lung development and causing respiratory distress shortly after birth.^[2] While typically diagnosed prenatally or in the immediate newborn period, this case report describes an unusual presentation of CDH in a 3-month-old infant with a previously uneventful medical history.

CASE REPORT

A 3-month-old female infant, born to non-consanguineous parents, presented with sudden-onset respiratory distress. The pregnancy and birth history were uneventful, with no prenatal concerns or complications noted. The infant's postnatal course was also unremarkable until this sudden presentation. The case of this 3-month-old female infant underscores the rarity and unexpected nature of the delayed presentation of CDH in the absence of prenatal or immediate postnatal complications. A comprehensive literature review revealed no documented cases of delayed CDH presentation similar to this one.

Upon evaluation, the infant exhibited signs of respiratory distress, including rapid breathing and decreased breath sounds (reduced air entry) on one side of the chest. A chest X-ray was subsequently performed, revealing findings suggestive of CDH [Figure 1]. This delayed presentation of CDH is highly uncommon, as most cases are diagnosed prenatally through routine ultrasound scans or shortly after birth due to immediate respiratory difficulties.

This is an open-access article distributed under the terms of the Creative Commons Attribution-Non Commercial-Share Alike 4.0 License, which allows others to remix, transform, and build upon the work non-commercially, as long as the author is credited and the new creations are licensed under the identical terms.

©2024 Published by Scientific Scholar on behalf of Medicine India

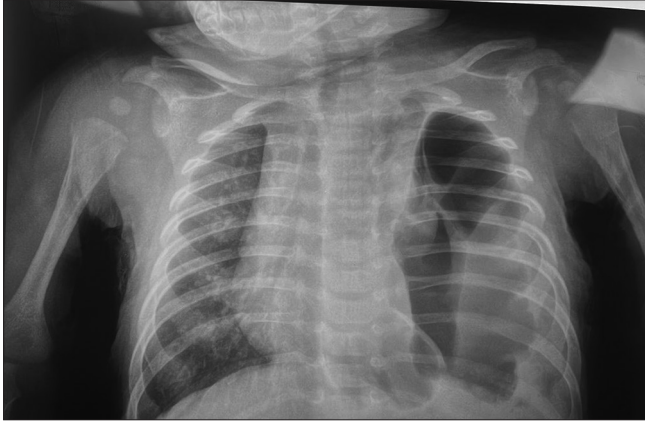


Figure 1: Chest X-ray anteroposterior view revealing findings of congenital diaphragmatic hernia

Given the critical nature of the diagnosis, the infant underwent immediate surgery to repair the diaphragmatic defect. The surgery aimed to reposition the herniated abdominal organs back into the abdomen and close the opening in the diaphragm. Fortunately, the surgery was successful, and the infant recovered well, currently being asymptomatic (without symptoms).^[3]

Post-operative care involved meticulous monitoring to ensure the infant's respiratory function remained stable and to prevent potential complications. Close attention was paid to the infant's nutritional needs, ensuring adequate support for optimal recovery and growth. In addition, ongoing assessment and follow-up were integral to detect any potential issues or recurrence of symptoms.

The favorable outcome of this case, with the infant currently asymptomatic and recovering well, is a testament to the effectiveness of early diagnosis and prompt surgical intervention. However, it also serves as a reminder of the importance of maintaining vigilance for CDH even beyond the neonatal period, particularly in cases where symptoms may be subtle or delayed. There is a need for continued research into the mechanisms and predictors of delayed presentation of CDH are crucial for enhancing diagnostic capabilities and refining management strategies. In addition, raising awareness among healthcare providers and caregivers about the possibility of CDH presenting later in infancy can help ensure timely recognition and intervention in similar cases.

Management

The primary treatment for CDH is surgery to repair the diaphragmatic defect and reposition the abdominal organs back into their proper place.^[4-6] The timing of surgery depends on the severity of the infant's condition. In critical cases, surgery may be necessary immediately after birth. In less severe cases, the surgeon might wait a few days or weeks to allow the infant to stabilize.

DISCUSSION

CDH is a relatively rare birth defect, affecting approximately 1 in 2,500–3,000 live births.^[6,7] The diaphragm plays a crucial role in respiration by separating the chest cavity from the abdomen and allowing the lungs to expand and contract during breathing. A defect in the diaphragm allows abdominal organs to push into the chest cavity, restricting lung development and compromising gas exchange in the lungs. This leads to respiratory distress, often observed immediately after birth. The severity of symptoms depends on the size and location of the diaphragmatic defect and the degree of lung hypoplasia (underdevelopment).

There are various types of CDH, classified based on the location of the diaphragmatic defect:^[8]

- Bochdalek hernia (most common, 70–80%): Defect in the posterolateral (back and side) portion of the diaphragm, typically on the left side.
- Morgagni hernia (less common, 20–25%): Defect in the anterior (front) portion of the diaphragm.
- Central hernia (rare): Defect in the central portion of the diaphragm.

The cause of CDH remains unclear; however, it is believed to be a combination of genetic and environmental factors. Non-consanguineous parents, as in this case, are more common in CDH births compared to consanguineous marriages.

The usual presentation of CDH involves immediate respiratory distress after birth. The infant may exhibit rapid breathing, retractions, cyanosis, and feeding difficulties. Diagnosis is typically confirmed through prenatal ultrasound or chest X-ray shortly after birth.^[9]

The delayed presentation of CDH, as seen in this case, is highly unusual. Several factors might contribute to this atypical presentation:

- Smaller herniation: A smaller diaphragmatic defect may have allowed for a less severe impact on lung development,^[10] delaying the onset of respiratory distress.
- Compensatory mechanisms: The infant's body might have developed compensatory mechanisms to manage the compromised lung function for the first few months of life.
- Misinterpretation of symptoms: Early symptoms, if present, might have been mild or misinterpreted by the parents, leading to a delayed diagnosis.

The importance of this case lies in highlighting the possibility of delayed presentation of CDH.

CONCLUSION

This case presentation is unique due to the delayed diagnosis of CDH at 3 months of age. The infant's

uneventful prenatal and postnatal course makes this even more unusual. While the exact reason for the delayed presentation remains unknown, it is possible that the diaphragmatic defect was smaller initially, allowing for relatively normal breathing in the early months. However, as the infant grew, the size of the defect or the herniated organs might have increased, leading to a more significant compromise of lung function and the subsequent development of respiratory distress.

Ethical approval

The Institutional Review Board has waived the ethical approval for this study

Declaration of patient consent

The authors certify that they have obtained all appropriate patient consent.

Financial support and sponsorship

Nil.

Conflicts of interest

There are no conflicts of interest.

Use of artificial intelligence (AI)-assisted technology for manuscript preparation

The authors confirm that there was no use of artificial intelligence (AI)-assisted technology for assisting in the writing or editing of the manuscript and no images were manipulated using AI.

REFERENCES

1. Kosiński P, Wielgoś M. Congenital diaphragmatic hernia: Pathogenesis, prenatal diagnosis and management-literature review. *Ginekol Pol* 2017;88:24-30.
2. Zhang X, Kramer MS. Variations in mortality and morbidity by gestational age among infants born at term. *J Pediatr* 2009;154:358-62, 362.e1.
3. Testini M, Girardi A, Isernia RM, De Palma A, Catalano G, Pezzolla A. Emergency surgery due to diaphragmatic hernia: Case series and review. *World J Emerg Surg* 2017;12:23.
4. Baerg J, Kanthimathinathan V, Gollin G. Late-presenting congenital diaphragmatic hernia: Diagnostic pitfalls and outcome. *Hernia* 2012;16:461-6.
5. Kotecha S, Barbato A, Bush A, Claus F, Davenport M, Delacourt C, *et al.* Congenital diaphragmatic hernia. *Eur Respir J* 2011;39:820-9.
6. Sola JE, Bronson SN, Cheung MC, Ordonez B, Neville HL, Koniaris LG. Survival disparities in newborns with congenital diaphragmatic hernia: A national perspective. *J Pediatr Surg* 2010;45:1336-42.
7. Kitagawa M, Hislop A, Boyden EA, Reid L. Lung hypoplasia in congenital diaphragmatic hernia. A quantitative study of airway, artery and alveolar development. *Br J Surg* 1971;58:342-6.
8. Areechon W, Reid L. Hypoplasia of lung with congenital diaphragmatic hernia. *Br Med J* 1963;1:230-3.
9. Dillon E, Renwick M, Wright C. Congenital diaphragmatic herniation: Antenatal detection and outcome. *Br J Radiol* 2000;73:360-5.
10. Klaassens M, De Klein A, Tibboel D. The etiology of congenital diaphragmatic hernia: Still largely unknown? *Eur J Med Genet* 2009;52:281-6.

How to cite this article: Ganesh V. Intriguing presentation of congenital diaphragmatic hernia. *Med India*. 2024;3:83-5. doi: 10.25259/MEDINDIA_17_2024